

HACETTEPE UNIVERSITY
DEPARTMENT OF GASTROENTEROLOGY

SIGMOIDOSCOPY REPORT

Informations:

Patient's File ID: 2123231
Name-Surname: George Clement
Age: 54
Sex: M
Date of Procedure 13-Eylül-2010
Physician: Professor Doctor , M.D.
Indication: Rectal bleeding
Preparation: ECG, IV hydration, IV line, Sedation
Premedication: Dormicum IV

a: Anal Canal

Image 1

Findings:

Anal Canal: Hemorrhoids
Rectum: Normal
Sigmoid: Normal
Decending Colon: Normal

b: Rectum

Image 2

Results:

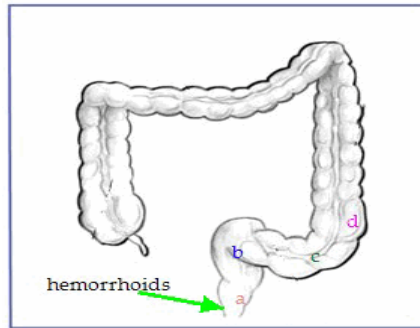
Biopsy: Not taken
Complication: No
Impression: Normal
Plan: Medication

c: Sigmoid Colon

Image 3

d: Descending Colon

Image 4



Signature:

Professor Doctor , M.D.