

HACETTEPE UNIVERSITY
DEPARTMENT OF GASTROENTEROLOGY

E.R.C.P. REPORT

Informations:

Patient's File ID: 2123231
Name-Surname: George Clement
Age: 54
Sex: M
Date of Procedure: 13-Eylül-2010
Physician: Professor Doctor , M.D.
Indication: Pain
Preparation: IV, ECG, Sedation
Premedication: Dormicum IV

a: Image location 1

Image 1

Findings:

Duodenum
D1: Normal
D2: Normal
Papilla: Normal
Common B. Duct Normal
Gall Bladder: Normal
Cystic Duct: Normal
Pancreatic Duct: Normal

b: Image location 2

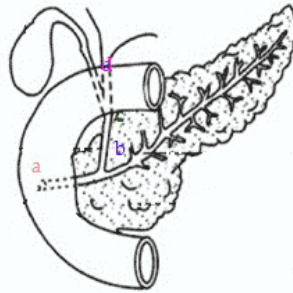
Image 2

Results:

Biopsy: Not taken
Complication: No
Impression: Normal ERCP
Plan: Control

c: Image location 3

Image 3



d: Image location 4

Image 4

Signature:

Professor Doctor , M.D.